

Unexpected favorable outcome to etoposide and cisplatin in a small cell lung cancer transformed patient: a case report

Zhanhong Xie, Yingying Gu, Xinqing Lin, Ming Ouyang, Yinyin Qin, Jiexia Zhang, Junjun Liu, Suiyi Mai & Chengzhi Zhou

To cite this article: Zhanhong Xie, Yingying Gu, Xinqing Lin, Ming Ouyang, Yinyin Qin, Jiexia Zhang, Junjun Liu, Suiyi Mai & Chengzhi Zhou (2019) Unexpected favorable outcome to etoposide and cisplatin in a small cell lung cancer transformed patient: a case report, *Cancer Biology & Therapy*, 20:9, 1172-1175, DOI: [10.1080/15384047.2019.1617561](https://doi.org/10.1080/15384047.2019.1617561)

To link to this article: <https://doi.org/10.1080/15384047.2019.1617561>



© 2019 The Author(s). Published with license by Taylor & Francis Group, LLC.



Published online: 04 Jun 2019.



Submit your article to this journal [↗](#)



Article views: 1963



View related articles [↗](#)



View Crossmark data [↗](#)



Citing articles: 2 View citing articles [↗](#)

Unexpected favorable outcome to etoposide and cisplatin in a small cell lung cancer transformed patient: a case report

Zhanhong Xie^a, Yingying Gu^b, Xinqing Lin^a, Ming Ouyang^a, Yinyin Qin^a, Jiexia Zhang^a, Junjun Liu^c, Suiyi Mai^c, and Chengzhi Zhou^a

^aDepartment of Medicine, Guangzhou Institute of Respiratory Disease, The First Affiliated Hospital of Guangzhou Medical University, Guangzhou, China; ^bDepartment of Pathology, The First Affiliated Hospital of Guangzhou Medical University, Guangzhou, China; ^cBurning Rock Biotech, Guangzhou, China

ABSTRACT

Patients with epidermal growth factor receptor (EGFR) mutant non-small cell lung cancer can benefit significantly from EGFR tyrosine-kinase inhibitors (TKIs) treatment, but almost every patient will inevitably develop resistance. The transformation to small cell lung cancer (SCLC) has been described as an EGFR-TKI resistance often associated with aggressive clinical course and poor prognosis. In this study, we report an unexpected favorable response to etoposide and cisplatin (EP) from an EGFR-mutant patient who developed SCLC transformation at disease progression after the administration of erlotinib with a progression-free survival of 7.7 months. At disease progression (PD) after erlotinib, rebiopsy showed typical SCLC histology accompanied by positive expressions of CD56, TTF-1, CK7, and synaptophysin. Subsequently, he was switched to standard SCLC treatment regimen EP in combination with erlotinib due to the retention of EGFR 19 del and achieved PR four cycles after the treatment. His disease progressed again 7.7 months after the initiation of EP treatment, with an enlargement of both primary and metastatic lesions. Collectively, this case illustrated the transformation from adenocarcinoma to SCLC and the subsequent durable benefit from standard treatment for SCLC.

ARTICLE HISTORY

Received 28 October 2018
Revised 20 March 2019
Accepted 28 April 2019

KEYWORDS

EGFR mutation; non-small-cell lung cancer; small-cell lung cancer transformation; etoposide and cisplatin; resistance mechanism

Introduction

The epidermal growth factor receptor (EGFR) -tyrosine kinase inhibitors (TKIs) have revolutionized the treatment for EGFR-mutant non-small-cell lung cancer (NSCLC).^{1–4} Despite initial efficacy, almost all patients will ultimately develop resistance, resulting in median PFS of approximately 12 months.⁵ Multiple molecular mechanisms underlying acquired resistance to EGFR-TKIs have been identified.^{6–8} The transformation to small-cell lung cancer (SCLC) has been described as a mechanism, occurring in 3–15% of patients.^{9–11} Patients developed SCLC transformation often present an aggressive clinical course with poor prognosis with a median overall survival of 6 months since the diagnosis of SCLC transformation.¹² Several studies have demonstrated an initial response to etoposide and cisplatin (EP) regimen but often develop resistance within a short time.^{13,14} Here, we report a 53-year-old male with metastatic EGFR-mutant lung adenocarcinoma (ADC) who developed SCLC transformation as resistance and subsequently benefited from etoposide and cisplatin with a PFS of 7.7 months.

Case report

A 53-year-old Chinese man with a smoking history of 20 years presented to our clinic with bloody sputum, fever, and back pain lasting for 20 days. He was found to have stage IV ADC(T4N3M1b) with multiple bone and bilateral adrenal

metastasis. Positron emission tomography-computed tomography revealed fluoro-2-deoxy-d-glucose-positive lesion measuring 3.3 × 5.8 × 5.0 cm in the left lower lobe (Figure 1(a)). He also had bronchial stenosis and occlusion and mediastinal lymphadenopathies. Emission computed tomography and magnetic resonance imaging revealed disseminated bone metastases and small nodules ischemia sites on the bilateral frontal and parietal lobes. Laboratory examinations revealed positive neuron-specific enolase (NSE) at 26.36 ng/mL, carcinoembryonic antigen at 3.99 ng/mL, and cytokeratin 19 fragment antigen 21-1 (CYFRA21-1) at 11.47 ng/mL in the serum (Figure 2). Mutation analysis by amplification refractory mutation system polymerase chain reaction showed EGFR exon 19 deletion. Immunohistochemistry staining showed an overexpression for hepatocyte growth factor receptor and lack of expression for anaplastic lymphoma kinase (ALK) and ROS proto-oncogene 1 receptor tyrosine kinase (ROS1).

The patient was administered erlotinib at 150 mg once daily orally and achieved partial response (PR) after 1.5 months based on Response Evaluation Criteria In Solid Tumors 1.1. On 16 May 2016, the patient returned to our clinic due to severe ostealgia. CT scan revealed an enlarged pleural mass measuring 3.8 × 4.0 × 5.0 cm (Figure 1(b)). Re-biopsy of the primary tumor revealed EGFR 19 del accompanied by SCLC transformation evident by positive expressions of CD56, TTF-1, CK7, and synaptophysin

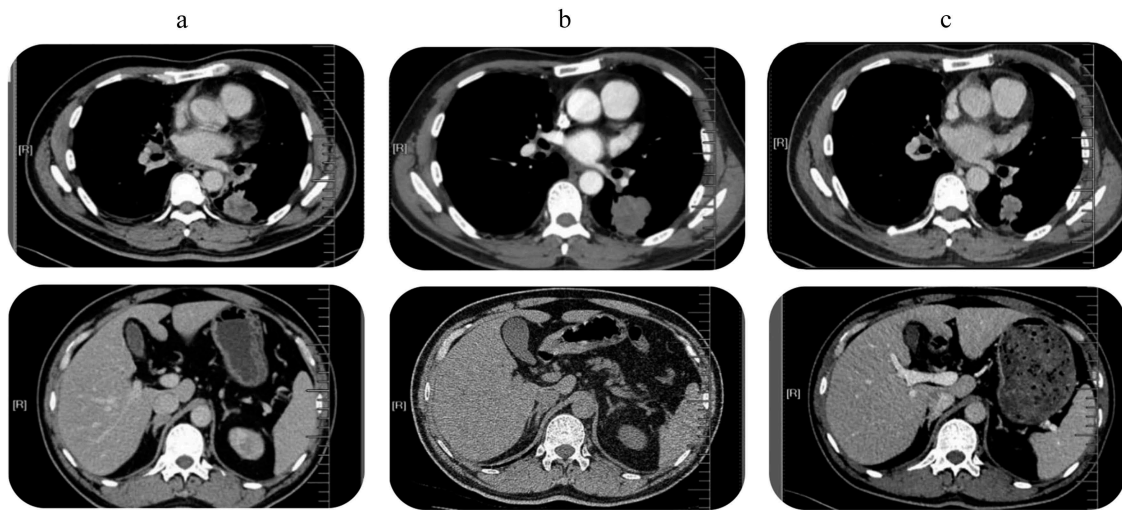


Figure 1. Tumor lesions detected by PET-CT. (a). Before the start of TKI treatment: central lung tumor in the left lower lobe mass infiltrating the hilum and mediastinum and bilateral adrenal metastases; (b). Progression after 6 months of erlotinib: enlarged pleural mass that showed transformation to SCLC. (c) Partial response after four cycles of EP chemotherapy and erlotinib continuation: Dramatic shrinkage of the primary lung tumor.

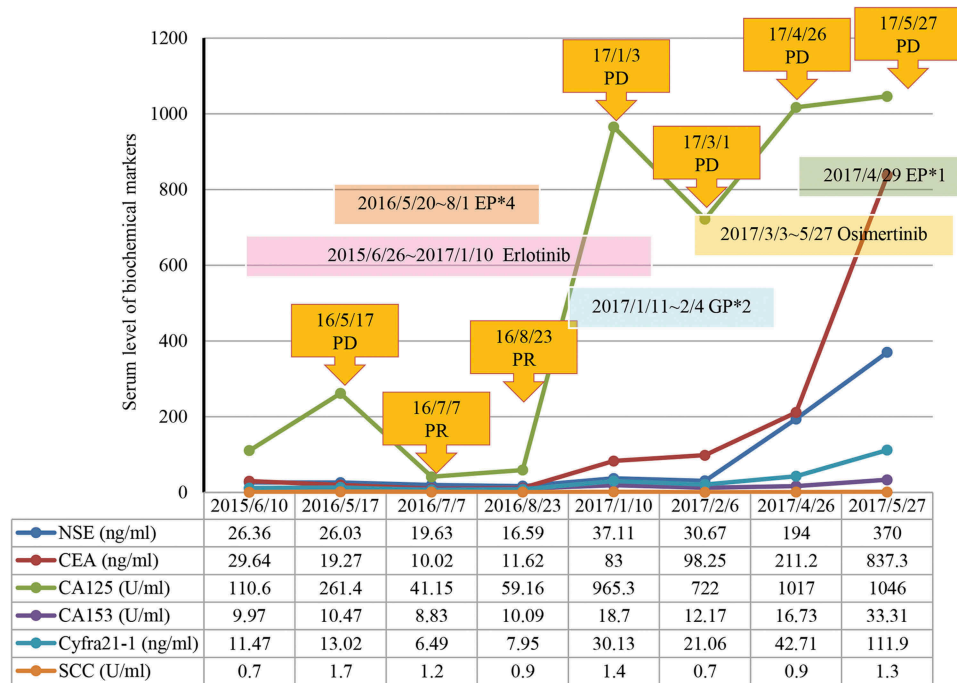


Figure 2. Variation curve of NSE, CEA, CA125, CA153, CYFRA21-1 and SCC. NSE, neuron-specific enolase; CEA, carcinoembryonic antigen; CA125, carcinoma antigen 125; CA153, carcinoma antigen 153; CYFRA21-1, cytokeratin 19 fragment antigen 21-1; SCC, squamous cell carcinoma antigen.

(Figure 3). H&E staining revealed typical SCLC histology consisting of nests of small cells (Figure 3). In addition, levels of NSE (26.03 ng/mL) and CYFRA21-1 (13.02 ng/mL) were also elevated (Figure 2). He was subsequently switched to standard etoposide (100 mg i.v. on days 1–5) and cisplatin (40 mg i.v. on days 1–3, once every 3 weeks) (EP regime) in combination with erlotinib. He achieved PR after four cycles (Figure 1(c)) and developed disease progression (PD) with an enlargement of primary and metastatic lesions after a PFS of 7.7 months. At PD, capture-based targeted sequencing of plasma sample revealed *EGFR* 19 del, T790M, *RBI*, and *TP53* mutations, and he was

subsequently switched to osimertinib (80 mg, qd) and had a PFS of 1.8 months. After disease progression, he only underwent palliative care.

Discussion

Numerous *EGFR*-TKI resistance mechanisms have been identified. Transformation of *EGFR*-mutant ADC to SCLC was recently proposed as a mechanism of acquired resistance to *EGFR*-TKIs.^{9,10} Numerous studies have documented such cases.^{15–17} Most patients who developed SCLC transformation are often associated with aggressive clinical behaviors and

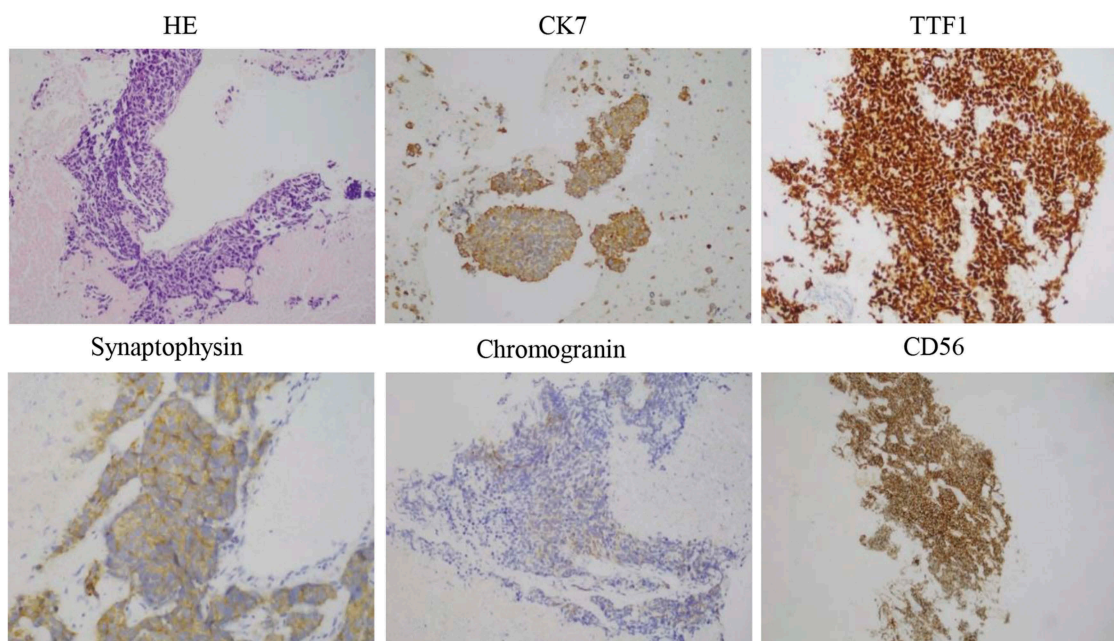


Figure 3. HE and IHC staining was performed on primary tumor biopsies after 6 months of erlotinib treatment. The cells displayed an SCLC phenotype with hyperchromatic nuclei, abundant cytoplasm, and inconspicuous nucleoli. Typical for SCLC, IHC was strongly positive for CD56 and TTF1, and focally for CK7 and synaptophysin (all 400 \times).

poor prognosis with a median overall survival (OS) of 6 months. Several studies have reported transient response to EP regimens after the development of SCLC transformation.^{17,18} Here, we reported an unexpected case of a favorable response to EP of an *EGFR*-mutant patient who developed SCLC transformation as resistance to erlotinib with a PFS of 7.7 months.

At PD after the exposure to erlotinib, the primary mass showed typical SCLC histology consisting of nests of small cells, which were positive for CD56, TTF-1, and focally positive for CK7 and synaptophysin (Figure 2), suggesting SCLC transformation. Capture-based targeted sequencing revealed concomitant loss-of-function mutations in retinoblastoma protein (*RBI*) and *TP53*, a typically molecular feature for SCLC, providing additional evidence for SCLC transformation. The dual mutations were rarely observed in NSCLC patients.^{10,19–21} The significant increase of NSE level, an important marker for SCLC, also indicated SCLC transformation.^{22,23} The mechanism underlying SCLC transformation remains elusive. Researchers have proposed two hypotheses: (1) the primary tumor is composed of both SDC and SCLC, and SCLC becomes dominant after the *EGFR*-TKI treatment. (2) After the exposure to *EGFR*-TKI, SCLC transdifferentiates from ADC.^{24,25} Molecular testing revealed that both the original and the transformed tumor at the time of resistance shared the *EGFR* 19 del, which suggests that SCLC transformation represents an evolution from the initial ADCs rather than a second coincident event.^{9,11} Historically, ADCs and SCLC share a common precursor with alveolar type II cells and that *EGFR* mutation could be a factor promoting SCLC transformation under the selective pressure of TKI therapy.^{10,19}

In summary, this case reported an unexpected favorable clinical response to EP with a PFS of 7.7 months of an *EGFR*-mutant lung ADC patient who underwent SCLC transformation as resistance to *EGFR*-TKI.

Acknowledgments

The authors would like to thank our patient for sharing his presentation for this manuscript.

Consent for publication

Written informed consent was obtained from the patient for the publication of this case report.

Disclosure of Potential Conflicts of Interest

The authors declare that they have no competing interests.

Ethics approval and consent to participate

The patient provided written informed consent and gave permission for the use of biopsies and publication of case details.

This study was approved by the Ethical Committee of the First Affiliated Hospital of Guangzhou Medical University.

Funding

There was no source of funding for this research.

Availability of data and materials

The data and materials in the current study are not available to any readers since they contain the patient's personal particulars.

Authors' contributions

Xinqing Lin, Ming Ouyang, Yinyin Qin, Jiexia Zhang and Chengzhi Zhou were involved in diagnostic flow and patient follow-up. Junjun Liu and Suiyi Mai contributed to the interpretation of published data and were involved in drafting of the manuscript. Yingying Gu is a licensed

pathologist. All the authors read and gave their final approval of the version to be published.

References

- Mok TS, Wu YL, Thongprasert S, Yang CH, Chu DT, Saijo N, Sunpaweravong P, Han B, Margono B, Ichinose Y, et al. Gefitinib or carboplatin-paclitaxel in pulmonary adenocarcinoma. *J Evidence-Based Med.* 2011;361:947.
- Mitsudomi T, Morita S, Yatabe Y, Negoro S, Okamoto I, Tsurutani J, Seto, T., Satouchi, M., Tada, H., Hirashima, T., et al. Gefitinib versus cisplatin plus docetaxel in patients with non-small-cell lung cancer harbouring mutations of the epidermal growth factor receptor (wjtg3405): an open label, randomised phase 3 trial. *Lancet Oncol.* 2010;11:104–105. doi:10.1016/S1470-2045(09)70390-0.
- Maemondo M, Inoue A, Kobayashi K, Sugawara S, Oizumi S, Isobe H, Gemma A, Harada M, Yoshizawa H, Kinoshita I, et al. Gefitinib or chemotherapy for non-small-cell lung cancer with mutated egfr | nejm. *N Engl J Med.* 2010;362:2380. doi:10.1056/NEJMoa0909530.
- Rosell R, Carcereny E, Gervais R, Vergnenegre A, Massuti B, Felip E, Palmero R, Garcia-Gomez R, Pallares C, Sanchez JM, et al. Erlotinib versus standard chemotherapy as first-line treatment for european patients with advanced egfr mutation-positive non-small-cell lung cancer (eurtac): A multicentre, open-label, randomised phase 3 trial. *Lancet Oncol.* 2012;13:239–246. doi:10.1016/S1470-2045(11)70393-X.
- Engelman JA, Jänne PA. Mechanisms of acquired resistance to epidermal growth factor receptor tyrosine kinase inhibitors in non-small cell lung cancer. *Clin Cancer Res.* 2008;14:2895–2899. doi:10.1158/1078-0432.CCR-07-2248.
- Kobayashi S M.D, PhD, Boggon TJ PhD, Dayaram T, Jänne PA, Kocher O, Meyerson M, Johnson BE, Eck MJ, Tenen DG, Halmos B. Mutation and resistance of non-small-cell lung cancer to gefitinib. *N Engl J Med.* 2005;352:786–792. doi:10.1056/NEJMoa044238.
- Engelman JA, Zejnullahu K, Mitsudomi T, Song Y, Hyland C, Park JO, Lindeman N, Gale C-M, Zhao X, Christensen J, et al. Met amplification leads to gefitinib resistance in lung cancer by activating erbb3 signaling. *Science.* 2007;316:1039–1043. doi:10.1126/science.1141478.
- Suda K, Tomizawa K, Fujii M, Murakami H, Osada H, Maehara Y, Yatabe Y, Sekido Y, Mitsudomi T. Epithelial to mesenchymal transition in an epidermal growth factor receptor-mutant lung cancer cell line with acquired resistance to erlotinib. *J Thorac Oncol.* 2011;6:1152–1161. doi:10.1097/JTO.0b013e318216ee52.
- Sequist LV, Waltman BA, Diassantagata D, Digumarthy S, Turke AB, Fidias P, Bergethon K, Shaw AT, Gettinger S, Cospser AK, et al. Genotypic and histological evolution of lung cancers acquiring resistance to egfr inhibitors. *Sci Transl Med.* 2011;3:75ra26. doi:10.1126/scitranslmed.3002003.
- Oser MG, Niederst MJ, Sequist LV, Engelman JA. Transformation from non-small-cell lung cancer to small-cell lung cancer: molecular drivers and cells of origin. *Lancet Oncol.* 2015;16:e165–e172. doi:10.1016/S1470-2045(14)71180-5.
- Norkowski E, Ghigna MR, Lacroix L, Le CT, Å F, Darteville P, Dorfmueller P, Thomas de Montpréville V. Small-cell carcinoma in the setting of pulmonary adenocarcinoma: new insights in the era of molecular pathology. *J Thorac Oncol.* 2013;8:1265–1271. doi:10.1097/JTO.0b013e3182a407fa.
- Roca E, Gurizzan C, Amoroso V, Vermi W, Ferrari V, Berruti A. Outcome of patients with lung adenocarcinoma with transformation to small-cell lung cancer following tyrosine kinase inhibitors treatment: A systematic review and pooled analysis. *Cancer Treat Rev.* 2017;59:117–122. doi:10.1016/j.ctrv.2017.07.007.
- Hwang KE, Jung JW, Oh SJ, Park MJ, Shon YJ, Choi KH, Jeong E-T, Kim H-R. Transformation to small cell lung cancer as an acquired resistance mechanism in egfr-mutant lung adenocarcinoma: A case report of complete response to etoposide and cisplatin. *Tumori.* 2015;101:e96–8. doi:10.5301/tj.5000276.
- Lu H, Chen B, Qin J, Xie F, Han N, Huang Z. Transformation to small-cell lung cancer following treatment with icotinib in a patient with lung adenocarcinoma. *Oncol Lett.* 2018;15:5799–5802. doi:10.3892/ol.2018.8040.
- Liu Y. Small cell lung cancer transformation from egfr-mutated lung adenocarcinoma: A case report and literatures review. *Cancer Biol Ther.* 2018;19:445–449. doi:10.1080/15384047.2018.1435222.
- Nishikawa S, Tambo Y, Ninomiya H, Oguri T, Kawashima Y, Takano N, Kitazono S, Ohyanagi F, Horiike A, Yanagitani N, et al. A case treated with nivolumab after small cell lung cancer transformation of mutant egfr non-small cell lung cancer. *Annals Oncol.* 2016;27(12):2300–2303. doi:10.1093/annonc/mdw431.
- Santoni-Rugiu E, Grauslund M, Melchior LC, Costa JC, Sorensen JB, Urbanska EM. Heterogeneous resistance mechanisms in an egfr exon 19-mutated non-small cell lung cancer patient treated with erlotinib: persistent fgfr3-mutation, localized transformation to egfr-mutated sclc, and acquired t790m egfr-mutation. *Lung Cancer.* 2017;113:14–17. doi:10.1016/j.lungcan.2017.08.024.
- Watanabe S, Sone T, Matsui T, Yamamura K, Tani M, Okazaki A, Kurokawa K, Tambo Y, Takato H, Ohkura N, et al. Transformation to small-cell lung cancer following treatment with egfr tyrosine kinase inhibitors in a patient with lung adenocarcinoma. *Lung Cancer.* 2013;82:370–372. doi:10.1016/j.lungcan.2013.06.003.
- Dorantesheredia R, Ruizmorales JM, Canogarcía F. Histopathological transformation to small-cell lung carcinoma in non-small cell lung carcinoma tumors. *Transl Lung Cancer Res.* 2016;5:401–412. doi:10.21037/tlcr.2016.07.10.
- Niederst MJ, Sequist LV, Poirier JT, Mermel CH, Lockerman EL, Garcia AR, Katayama R, Costa C, Ross KN, Moran T, et al. Rb loss in resistant egfr mutant lung adenocarcinomas that transform to small-cell lung cancer. *Nat Commun.* 2015;6:6377. doi:10.1038/ncomms7377.
- Lee JK, Lee J, Kim S, Kim S, Youk J, Park S, An Y, Keam B, Kim D-W, Heo DS, et al. Clonal history and genetic predictors of transformation into small-cell carcinomas from lung adenocarcinomas. *J Clin Oncol.* 2017;35:3065–3074. doi:10.1200/JCO.2016.71.9096.
- Isgrò MA, Bottoni P, Scatena R. Neuron-specific enolase as a biomarker: biochemical and clinical aspects. In: *Adv Cancer Biomarkers.* 2015;867:125–143. doi:10.1007/978-94-017-7215-0_9.
- Zhang Y, Li XY, Tang Y, Xu Y, Guo WH, Li YC, Liu X-K, Huang C-Y, Wang Y-S, Wei Y-Q. Rapid increase of serum neuron specific enolase level and tachyphylaxis of egfr-tyrosine kinase inhibitor indicate small cell lung cancer transformation from egfr positive lung adenocarcinoma? *Lung Cancer.* 2013;81:302–305. doi:10.1016/j.lungcan.2013.04.005.
- Gazdar AF, Minna JD. Deregulated egfr signaling during lung cancer progression: mutations, amplicons, and autocrine loops. *Cancer Prev Res.* 2008;1:156–160. doi:10.1158/1940-6207.CAPR-08-0080.
- Politi K, Zakowski MF, Fan PD, Schonfeld EA, Pao W, Varmus HE. Lung adenocarcinomas induced in mice by mutant egf receptors found in human lung cancers respond to a tyrosine kinase inhibitor or to down-regulation of the receptors. *Genes Dev.* 2006;20:1496–1510. doi:10.1101/gad.1417406.